

# PHAKO BEI PEX

KAT 13


lockere Zonulae und subluxierte Linse

Dr.med. Catharina Latz

21. Juni 2024

[www.menti.com](https://www.menti.com)  
code **3300 4250**



A black and white photograph of a statue of Sun Tzu, a Chinese general and philosopher. The statue is shown from the chest up, wearing a traditional Chinese military helmet and a high-collared robe. It has a beard and a mustache, and is looking slightly to the right. The background is dark.

Know your enemy and  
know yourself  
and  
you can fight a hundred battles  
without disaster

Sun Tzu



# PHAKO BEI PEX

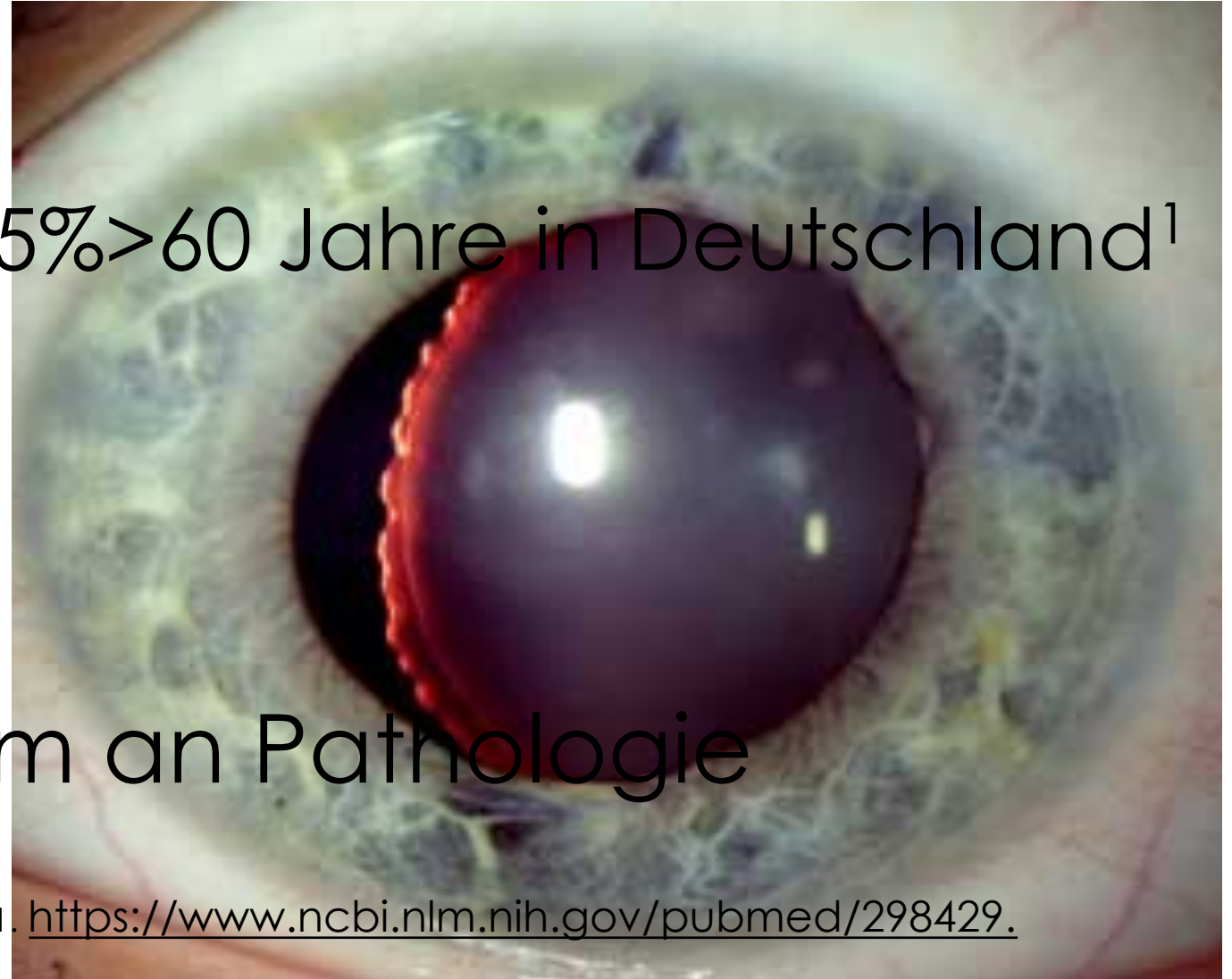1. prä-
2. intra- operativ
3. post-



# PRÄOPERATIV

- häufig
- progressiv
- systemisch
- breites Spektrum an Pathologie

5% > 60 Jahre in Deutschland<sup>1</sup>



1. <https://www.ncbi.nlm.nih.gov/pubmed/298429>.

Stress

Oxidative Stress/UV

Ischemia Hypoxia

Mechanical stress

pathogenetisches Konzept

Entzündung

Inflammatory mediators (IL-6/8)

Growth factors (TGF- $\beta$ 1, CTGF) ↑

Fibrotic stress response

LOXL1 genotype


TIMPs ↑  
MMPs ↓

*Perpetuation of TGF- $\beta$  signaling  
Increased expression of:  
elastic proteins and  
cross-linking enzymes (LOXL1)*

Fibrillen

*Protein aggregation/cross-linking  
Proteasome dysfunction  
Dysregulated autophagy  
Impaired matrix degradation*

# PATHOPHYSIOLOGIE



# KLINISCHES BILD

Zonulae	Zonulolyse, Phakodonesis
Iris	insuffiziente Mydriasis
Hornhaut	Hornhautdekomensation
Trabekelmaschenwerk	Glaukom

Every battle is won  
before  
it's fought.

Sun Tzu





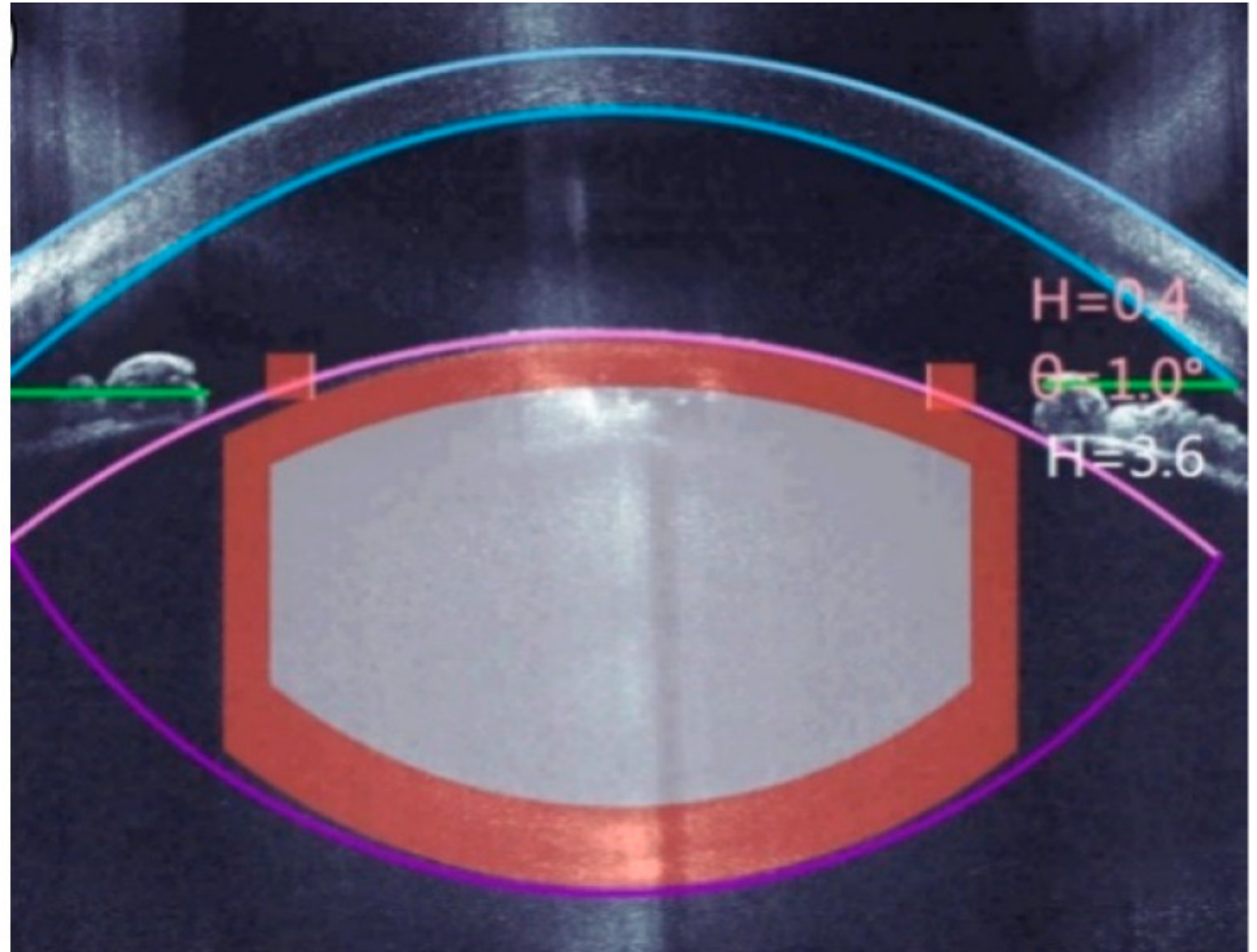
# INTRAOPERATIV

Iris	insuffiziente Mydriasis	mechanische Mydriase pharmakologische M.
Zonulae	Zonulolyse, Phakodonesis	Schonung
Hornhaut	Hornhautdekomensation	Schonung
TMW	Glaukom	Trabekelwerksaspiration



RHEXIS

Rip vs. Shear  
Gegendruck  
Femtolaser





# MOBILISATION

Cortical Cleavage  
Hydrodissection  
nach Howard Fine

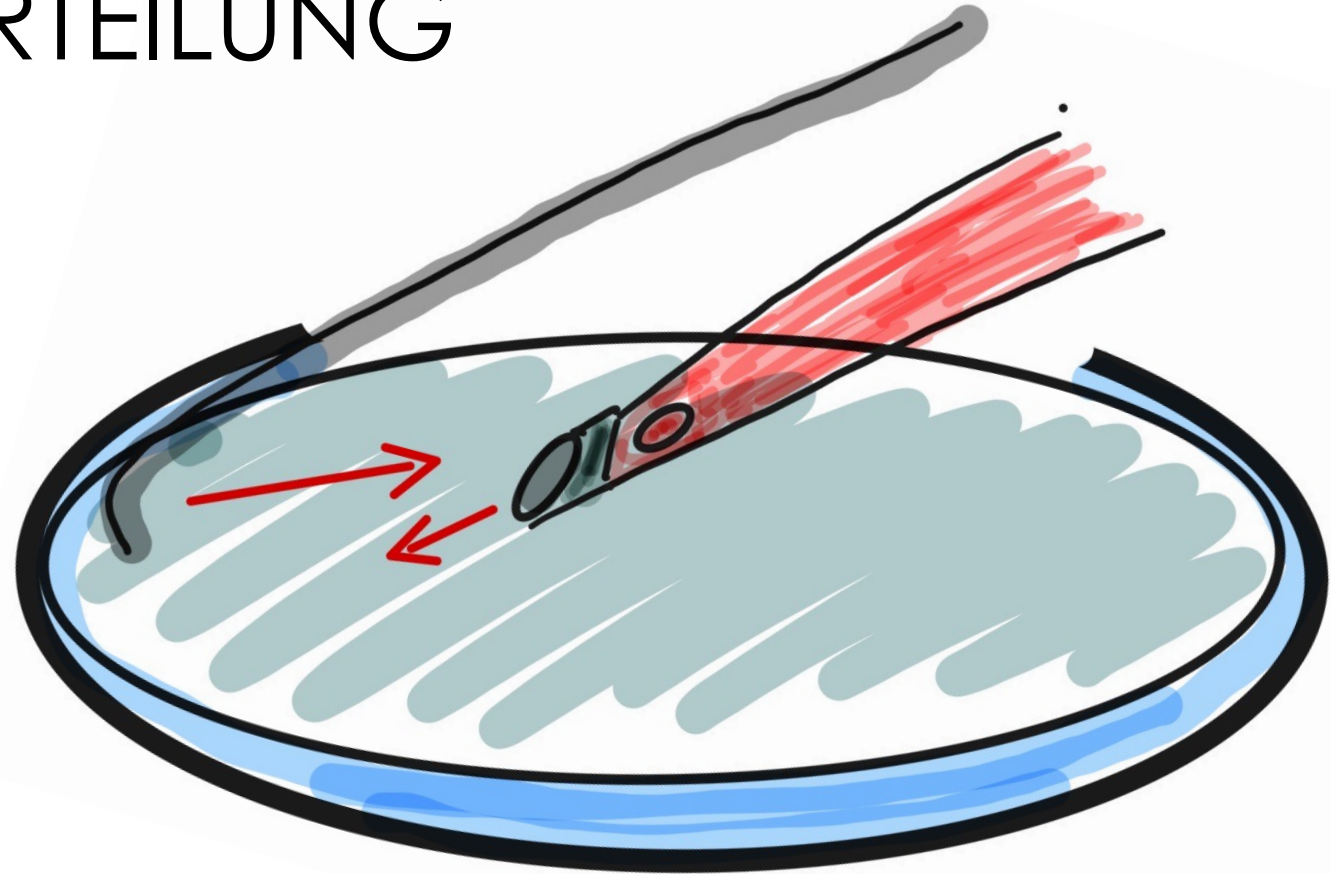




# KERNZERTEILUNG

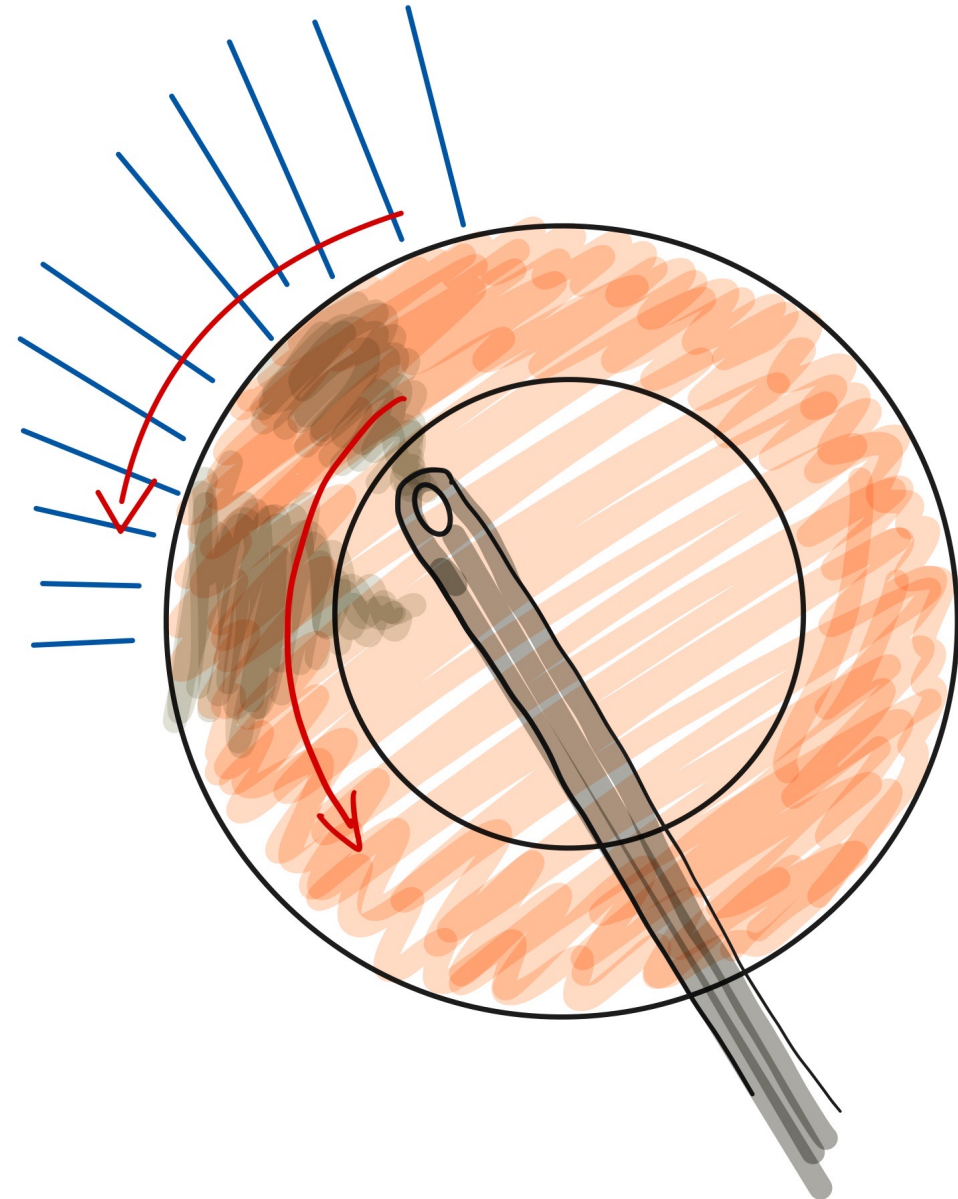
Chop

Femto





Hydrodissektion  
tangential  
zum Defekt





# IOI IMPLANTATION

Viskoelastikum


hydrophobe IOI



# KAPSELHÄKCHEN

früher Einsatz

alternativ Irishäkchen



MST Capsule Retractors

MCR-0001



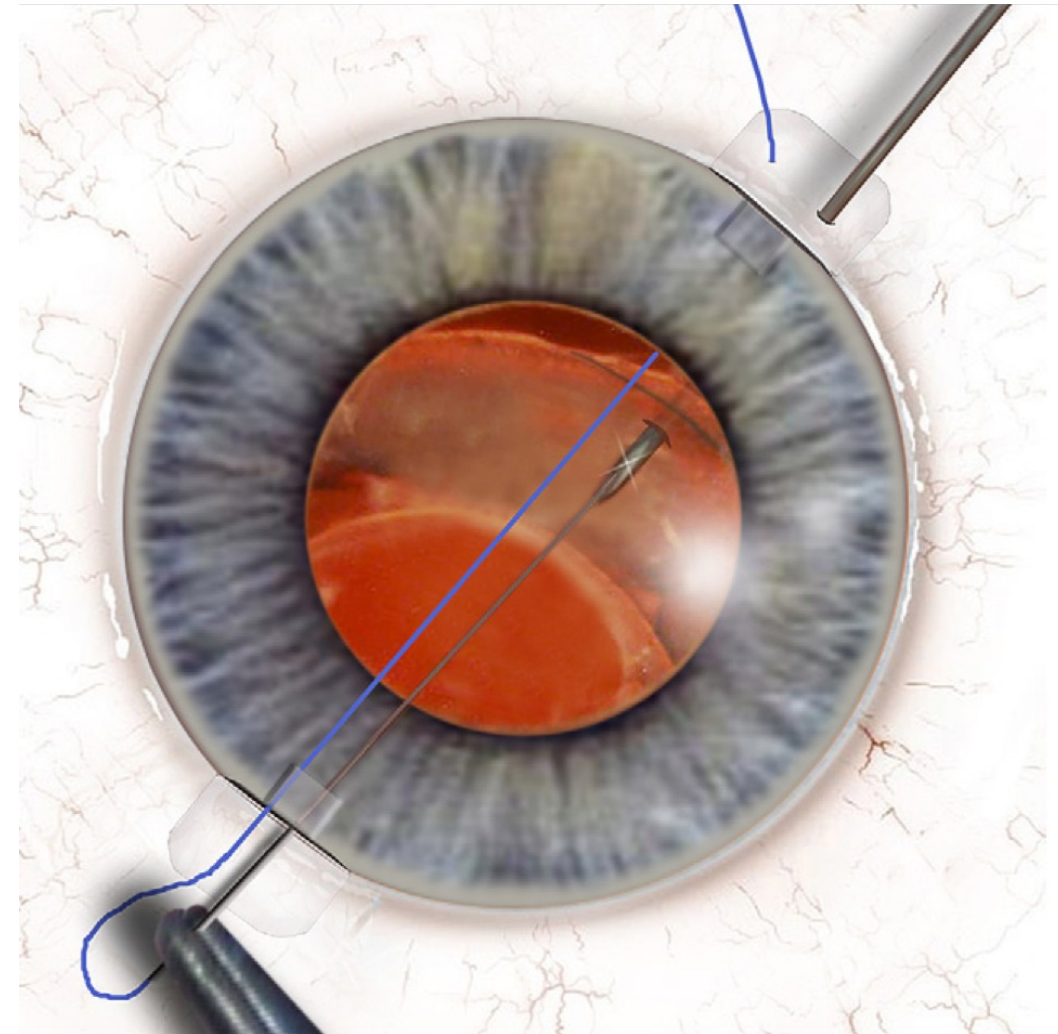
# ZONULOLYSE > 5 UHRZEITEN

Cionni-Ring

Ahmed Segment

Fixierung

(Naht, Prolene, Gortex,  
glued, Häkchen,  
Hoffmann Pocket)







# ABSOLUTE ZONULOLYSE

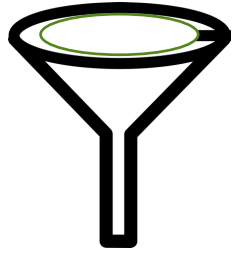während Phako:

ECCE

Viskolevitation

alternative IOL Fixierung

(Verysyse, Canabrava, Yamane)



## INTRAOPERATIV

- intracameral  
Phenylephrin
- mechanische  
Mydriasis
- Endothelschonung
- große Rhexis
- Zonulaschonung
- hydrophobe IOL
- alternative Linsenentfernung
- alternative Linsenfixierung
- Trabekelwerksaspiration



## POSTOPERATIV

- IOD Kontrolle
  - Glaucox, TWA
- Anti-Inflammation



## PHAKO BEI PEX

- sehr gute Ergebnisse möglich
- gute Vorbereitung
- Hilfsmittel einsetzen
- Zonulaschonung
- Lebenserwartung und Progressivität von PEX kalkulieren